

Original Article

Report of two pregnant cases with disseminated peritoneal leiomyomatosis

Pathology

Abeer S. Farag¹, Ashraf S. Abolouz²

¹Pathology Department, faculty of Medicine for Girls, Cairo, Al-Azhar University, Egypt.

²Obstetrics and Gynecology Department, October 6th University, Giza, Egypt.

ABSTRACT

Background: Leiomyomatosis peritonealis disseminata (LPD) is very occasional disorder noted by formation of numerous nodules which spread across the peritoneal and omental surfaces. It is a benign¹³ disease of unknown etiology and usually occurs in women of childbearing age.

Cases: This case report study included two cases. The first one is a 29 years-old female hospitalized for an elective cesarean section. A large omental mass and multiple small nodules in the ovary and intestine were observed incidentally after fetal delivery and expulsion of the uterus that was initially considered as leiomyosarcoma. The histopathology and immune-histochemistry of the masses were consistent with the diagnosis of DPL. The second one is a case of 30 weeks pregnant women presented with acute abdominal pain. Her age was 31-years-old. She was hospitalized for diagnosis and management. Investigations showed elevated inflammatory serum markers. An exploratory laparotomy was performed at 30 weeks of gestation to confirmed presence of tumors. All visible tumors were removed. In the subsequent pregnancy evidence of recurrent LPD lesions with no symptoms will be expected in such cases.

Objective: The main objective of this case report is to clarify the role of immunohistochemistry in the diagnosis of LPD and to differentiate it from other mimic malignant peritoneal tumors. Also, to simplify the clinical data regarding delivery and follow-up information for patients with LPD that developed during pregnancy.

JRAM 2022; 3(2): 131-135

Keywords: Case study report, disseminated peritoneal leiomyomatosis, pregnancy; immunohistochemistry.

Submission Date: 2 December 2021

Acceptance Date: 30 January 2022

Corresponding Author: Abeer S Farag¹ Pathology department, faculty of medicine for girls, Cairo, Azhar university, Egypt. **Tel: +201093009511. E-mail:** abeersaid.medg@azhar.edu.eg, abeer_said123@yahoo.com

Please cite this article as: Farag AS and Abolouz AS. Report of two pregnant cases with disseminated peritoneal leiomyomatosis. *JRAM 2022; 3(2): 131-135. DOI: 10.21608/jram.2022.109247.1150*

INTRODUCTION

Leiomyomatosis peritonealis disseminata (LPD) is a rare benign tumor characterized by the 41 widespread dissemination of proliferating smooth muscle nodules throughout the peritoneum, omentum and pelvic structures^[1]. It resembles uterine leiomyoma on both macroscopic and microscopic pictures but display unusual sites with recurrent and malignant predispositions^[2]. The first case was described in 1952 by Wilson and Peale. Lesions occur most commonly in women of childbearing period, but a rare case occur in postmenopausal women and in men^[3].

These lesions are usually asymptomatic and incidentally found during surgery or gynecological ultrasound examination but may be also present with abdominal pain prompting investigation^[4]. The etiology of the disease is still poorly understood, but some authors believe that the possible causes for this could be genetic, metaplasia of subperitoneal mesenchymal stem cells or hormonal^[5]. Female gonadal steroids play an important role in the pathogenesis of LPD, as this condition usually

associated with high levels of exogenous or endogenous female gonadal steroids, such as pregnancy, prolonged exposure to oral contraceptives and/or combined hormonal replacement therapy and estrogen-secreting tumors^[6].

Disseminated peritoneal leiomyomatosis during pregnancy is rare and sometimes incidentally diagnosed during the delivery with caesarian section^[7]. There is no definite consent about the adverse effects of LPD on pregnancy, the potential for aggressiveness or recurrence and the safety of re-pregnancy in patient with a history of LPD. In this study, we reported two cases with LPD that occurred during pregnancy, and summarized 43 the obstetrics-related clinical data and follow-up, hoping to highlight the prognostic features of LPD

PRESENTATION OF CASES

Case 1

A 29-years-old woman was attended to Dar EL-Shefa hospital in a period from 2016 to 2020 for an elective

SC. Her previous pregnancy was also a SC due to the abnormal fetal position. Disseminated small multiple nodules mimicking malignant tumors, extending from the uterus over the intestine, peritoneum and abdominal viscera were incidentally noted during exploration of the abdominal cavity after delivery of fetus. The masses were purple, rubbery and polypoid of variable size. It is noticeable that none of the ultrasounds examination during pregnancy revealed presence of such masses and that the patient had not previously had any ultrasound examination of the abdomen before pregnancy.

Histopathological examination revealed multiple fascicles of proliferated benign looking spindle cells arranged in a fibro-vascular background with scattered clusters of decasualized cells. The spindle cells are positive for smooth muscle action (SMA) and Desmin (Figure 1) (but were negative for CD117 and DOG1. Histopathological and Immunohistochemical findings were in favor of DPL. The patient was discharged on the tenth day after surgery and the patient underwent several ultrasounds revealed no nodules were seen on uterus or elsewhere in follow up (24 month).

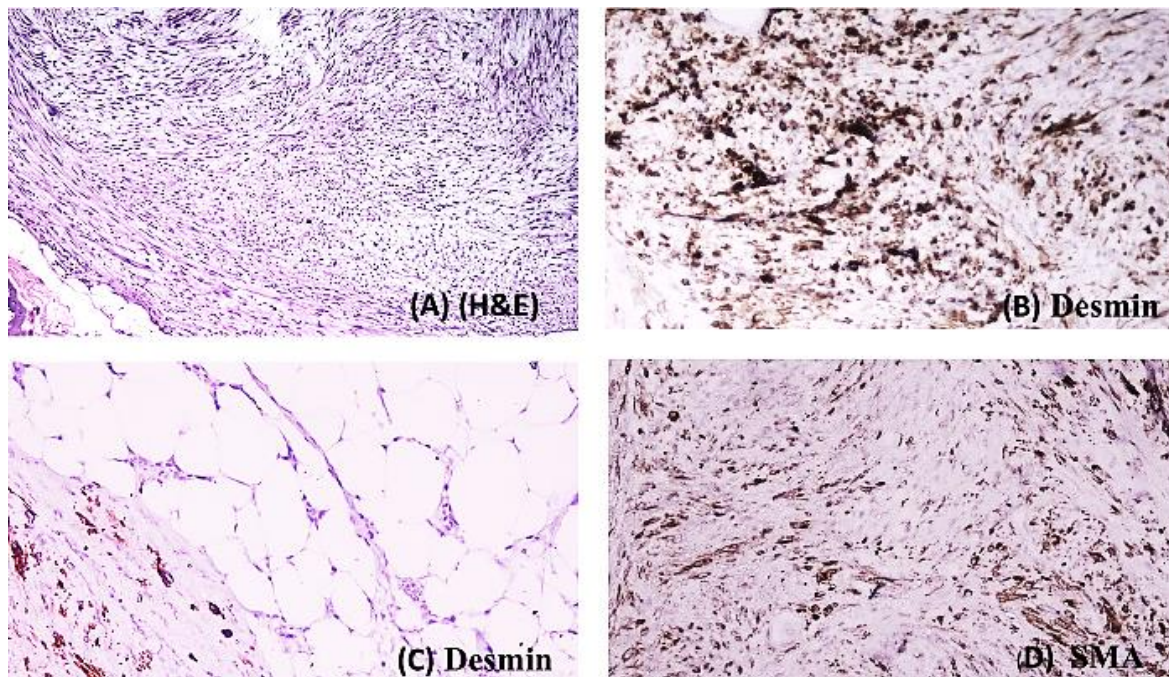


Figure (1): (A) Histopathological examination showed benign looking bundles of smooth muscle cells with mild cellularity without atypia, mitosis, or necrosis (H&E 200). Immunohistochemical evaluation is strong positive for Desmin (B). Positive for Desmin without infiltration to surrounding fat (C) and also moderately positive for SMA (D) (X 200)

Case 2

A 31-year-old woman, 30 weeks gestation, presented to her obstetrician with severe abdominal symptoms and elevated serum inflammatory markers. The patient has a history of laparoscopic myomectomy at age 22. She has no history of prolonged use of contraceptive pills. Pelvic ultrasound was firstly done by the obstetrician and revealed multiple pelvic masses and showed non-invasive behaviors, there was neither ascites nor lymphadenopathies, an MRI was done for confirmation. An exploratory laparotomy was done and revealed multiple pelvic and omental mass in the abdominal cavity and pelvis, which were excised. The macroscopic picture of the lesions demonstrated large polypoid partially solid masses mimicked a disseminated malignancy that fills the pelvis with multifocal firm gray, white nodules of different size (figure 2).

Histopathological examination of the nodules revealed interlacing fascicles of benign looking smooth muscle

cells. Immunohistochemical evaluation was strongly positive for the SMA, desmans but was negative for CD117 (figure 3).

Histopathological and Immunohistochemical (IHC) findings were consistent with DPL; the patient was discharged from the hospital on the tenth day after surgery. The first ultrasound examination was performed three months later on and showed a smooth surface of uterus without presence of any fibroid nodules. The patient was examined again three more times and no nodules were seen on uterus or elsewhere. The patient gets pregnant 22 months after surgery. At 9 weeks of pregnancy, US examination revealed a small nodule (2.2cm X2.9 cm) in the uterus, without symptoms. Strict follow up, prior time of delivery, the patient was admitted to hospital, and both the patient and the fetus were in good condition. After delivery, a hysterio-salpingo -oophorectomy was performed.

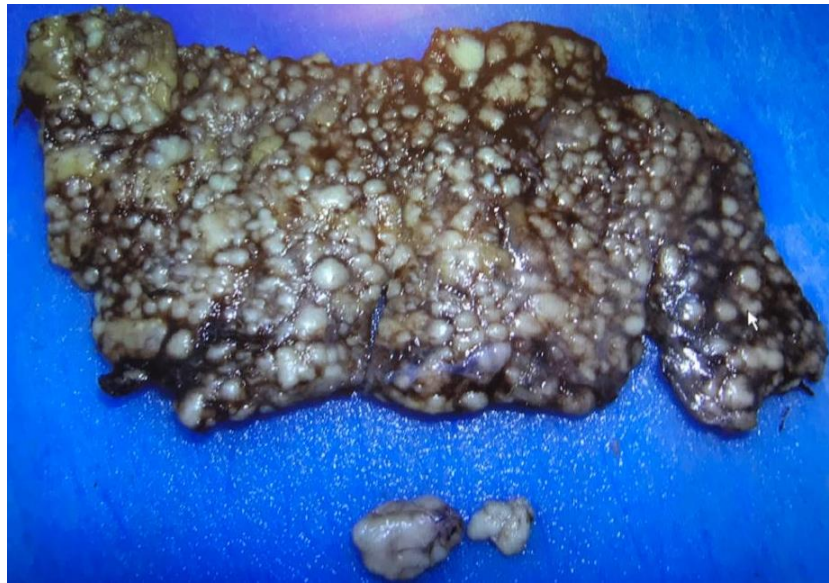

Figure (2): Large polypoid partially solid mass and multiple firm gray, white small nodules of variable size

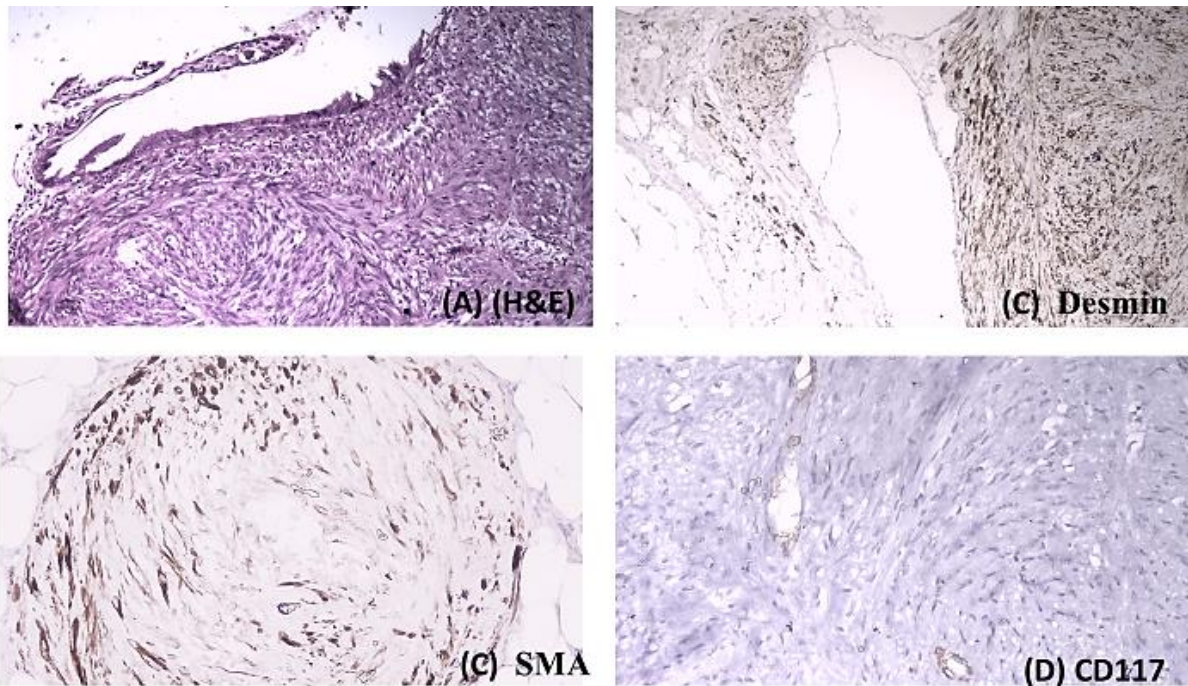


Figure (3): (A) Histopathological examination showed interlacing bundle of smooth muscle cells without atypia or mitosis (H & E 200). Immunohistochemical evaluation is positive for Desmin (B), SMA (c) and negative for CD117 (D) (X 200).

DISCUSSION

Disseminated peritoneal leiomyomatosis is unusual growth patterns of leiomyomas mimicking disseminated malignant neoplasms which make it more clinically and radiologically challenging [8].

The most important entity in the differential diagnosis of DPL is peritoneal carcinomatosis, malignant peritoneal mesothelioma, peritoneal gastrointestinal stromal tumor primary peritoneal serous carcinoma and metastatic leiomyosarcoma [9]. Until now, histopathological diagnosis and IHC needed to accurately diagnose of LPD. DPL is a rare disorder of young women but very rare cases have been seen in post-menopausal women [10], and during pregnancy,

sometimes 12 incidentally diagnosed during the delivery with caesarian section [7]. Excessive hormonal exposure and High levels of estrogen and progesterone occur during pregnancy seems to play an essential role in the development of LPD [11] [2]. The patients generally asymptomatic; however, abdominal pain or abdominal distension do occur [13]. Although the disease regresses most often spontaneously or with treatment, it can also persist for years and although LPD was a benign disease with good prognosis, the minority of cases becomes malignant [14].

Immunohistochemical analysis of the two cases showed strongly positive with Desmin and focally

positive with SMA, suggesting that LPD has molecular cytogenetic feature of uterine leiomyoma.

Surgical excision of all visible lesions remains a good option and may be a very effective treatment in symptomatic disease and in those with rapidly growing or recurrent lesions that are refractory to hormonal therapy^[7]. While this condition is a rare entity and the fact that the peritoneal myomas mimic malignant peritoneal tumors. The disease should be kept in mind in dealing with a patient with multifocal abdominal masses especially with history of a uterine leiomyoma to avoid misdiagnosed and unnecessary aggressive treatment and re-pregnancy may possible but with caution and follow up.

Financial support and sponsorship: This work not funded from any governmental or non-governmental agencies

Conflict of Interest: No direct or indirect conflict of interest

REFERENCES

1. **Shadi R, Alexander H, Jacqueline L, Mon-L, Sarina L, Andy L, et al.** Disseminated peritoneal leiomyomatosis (DPL); a case report and review of literature. *Obstetrics and Gynecology International Journal*. 2017; 7 (2): 00240.
2. **Marrone G, Crino F, Morsolini M, Caruso S, and Miraglia R.** Multidisciplinary approach 12 in the management of uterine intravenous leiomyomatosis with intracardiac extension: case 13 report and review of literature. *J Radiol Case Rep*. 2019; 13:1–13.
3. **Josh G and Roy G.** Disseminated peritoneal leiomyomatosis. *Applied radiology*. 2018 ; (1) :46-47.
4. **Xuechuan H, Yaug F and Yan Y.** Two cases of leiomyomatosis peritonealis 51 disseminata and Review of the Literature .*Obstet Gynecol Int J*. 2017; 6 (1): 00192.
5. **Al-Talib A and Tulandi T.** Pathophysiology and possible iatrogenic cause of leiomyomatosis peritonealis disseminata. *Gynecol Obstet Invest*. 2010; 69:239–44.
6. **Mozhdeh M, Maryam N, and Akbar S.** Disseminated peritoneal leiomyomatosis, *Iran J Med Sci*. 2011 ; 36 (1).
7. **Hualei B, Chengjuan J, Yan F, Yana M, Xiao W, Jingying Ch et al.** Successful pregnancy after complete resection of leiomyomatosis peritonealis disseminate without recurrence: a case report with next-generation sequencing analysis and 10 literature review , *World Journal of Surgical Oncology*. 2020; 18,
8. **Sweta S, Puneet P, and Satya N.** Disseminated peritoneal leiomyomatosis: an unusual presentation of intra-abdominal lesion mimicking disseminated malignancy. *Med Pharm Rep*. 2020; 93(1): 113–116.
9. **Levy AD, Arna’is J, Shaw JC, and Sobin LH.** Primary peritoneal tumors: imaging features with pathologic correlation. *RadioGraphics*. 2008; 28:583-586.
10. **Paul PG and Naik S.** Disseminated leiomyomatosis peritonei. Incidental finding in laparoscopy: a case report. *Surg Laparosc Endosc PercutanTech*. 2010; 20: e123-e124.
11. **Thian YL, Tan KH, Kwek JW, Wang J, Chern B, and Yam KL.** Leiomyomatosis peritonealis disseminata and subcutaneous myoma--a rare complication of laparoscopic myomectomy. *Abdom Imaging*. 2009; 34:235-8. 16.
12. **Summa B, Schem C, Weigel M, Strauss A, Jonat W, Maass N, et al.** Leiomyomatosis peritonealis disseminata in a pregnant woman. *Arch Gynecol Obstet*. 2010; 281: 123–7.
13. **Yang R, Xu T, Fu Y, Cui S, Yang S, and Cui M.** Leiomyomatosis peritonealis disseminata associated with endometriosis: a case report and review of the literature. *Oncol Lett*. 2015; 9: 717-20.
14. **Surmacki P, Sporny S, Tosiak A, and Lasota J.** Disseminated peritoneal leiomyomatosis coexisting with leiomyoma of the uterine body. *Arch Gynecol Obstet*. 2006; 273:301-303.

الملخص العربي

تقرير عن حالتين من حالات الحمل مصابة بالورم العضلي الأملس الصفاقي المنتشر

عبير سعيد فرج¹، أشرف صالح أبو اللوز²

¹قسم الباثولوجيا العامة، كلية طب بنات، القاهرة، جامعة الأزهر، جمهورية مصر العربية.

²قسم النساء والتوليد، جامعة 6 أكتوبر، الجيزة، جمهورية مصر العربية.

ملخص البحث

الخلفية: الورم العضلي الأملس الصفاقي المنتشر هو اضطراب عرضي للغاية يُلاحظ من خلال تكوين العديد من العقيدات التي تنتشر عبر الأسطح البريتونية والثومية. أنه مرض حميد 13 مجهول السبب ويحدث عادة عند النساء في سن الإنجاب.

الحالات: تضمنت دراسة تقرير الحالة هذه حالتين. الأولى هي امرأة تبلغ من العمر 29 عامًا تم إدخالها إلى المستشفى لإجراء عملية قيصرية اختيارية. لوحظ وجود كتلة ثقيلة كبيرة وعقيدات صغيرة متعددة في المبيض والأمعاء بشكل عرضي بعد ولادة الجنين الذي كان يعتبر في البداية ساركومة عضلية أملس. كانت الأنسجة المرضية والكيمياء النسيجية المناعية للكتلة متوافقة مع تشخيص الورم العضلي الأملس الصفاقي المنتشر. الحالة الثانية هي حالة امرأة حامل في الأسبوع الثلاثين من الحمل تعاني من آلام حادة في البطن. كان عمرها 31 عامًا. تم نقلها إلى المستشفى للتشخيص والعلاج. أظهرت الفحوصات ارتفاع علامات الالتهابية في المصل. تم إجراء فتح استكشافي للبطن في الأسبوع 30 من الحمل لتأكيد وجود الأورام. تمت إزالة جميع الأورام الظاهرة في الحمل اللاحق.

من المتوقع حدوث آفات متكررة من الورم العضلي الأملس الصفاقي المنتشر مع عدم وجود أعراض في مثل هذه الحالات.

الهدف: الهدف الرئيسي من عرض هاتين الحالتين هو توضيح دور الكيمياء الهستولوجية المناعية في تشخيص الورم العضلي الأملس الصفاقي المنتشر وتمييزها عن الأورام البريتونية الخبيثة الأخرى. أيضًا، لتبسيط البيانات السريرية المتعلقة بمعلومات الولادة والمتابعة للمرضى الذين يعانون من الورم العضلي الأملس الصفاقي المنتشر التي تطورت أثناء الحمل.

الكلمات المفتاحية: تقرير دراسة الحالة، الورم العضلي الأملس الصفاقي المنتشر، الحمل، المناعية.

الباحث الرئيسي:

الاسم: عبير سعيد فرج، قسم الباثولوجيا العامة، كلية طب بنات، القاهرة، جامعة الأزهر، جمهورية مصر العربية.

الهاتف: 201093009511

البريد الإلكتروني: abeer_said123@yahoo.com abeersaid.medg@azhar.edu.eg